

Histological Effect of Zinc Oxide Nanoparticles on Kidney of Japanese Quail *Coturnix coturnix*

Hanan R AbdAlaziz* and Azhar A Albaker

Department of Biology, University of Mosul, Mosul, Iraq

Abstract

During the last two decades, researchers interest of nanotechnology has increased, It is the main technology in the twenty-first century, as it has brought about many applications to diagnose and treat diseases, improve crop production, and revolutionize the poultry industry by using new tools in the partial treatment of diseases and improving the response of the productive performance of poultry, and this technology has entered all fields of different sciences, including biology, and search for the possibility of this technology to explain and treat different situations. The current study showed the effect of oxide zinc nanoparticles on the kidneys of quail birds. The acute treatment, by using 20 and 40 ppm concentration were dosed orally for three days, while the chronic treatment used 5 and 10 ppm concentration were given orally for thirty days. The results showed that the acute treatment cause necrosis of the renal epithelial cells, hemorrhage between the renal tubules and within the glomerulus, while the chronic treatment showed swelling, degeneration and necrosis of the epithelial cells lining renal tubules, with infiltration of inflammatory cells upon examination of sections appeared after a month of treatment.

Keywords: Drugs • Nanoparticles • Membrane • Kidneys

Introduction

Nanotechnology is the understanding and control of matter at the dimensions 1 and 100 nanometers [1]. Nanotechnologies are based on the manipulation, control and integration of atoms and molecules to form materials, structures, components, devices and systems at the nanoscale, Nanotechnology may be able to advance environmental protection [2]. One of the most important applications of nanomaterial in medicine is the delivery of drugs, and many studies are conducted on these applications, where the nanoparticles work to deliver the drugs that they carry to the diseases [3]. Supplementation of diets with nanoparticles has been accompanied by pathological changes in animal tissues, primarily in the organs [4,5]. Among other metal nanoparticles, zinc oxide nanoparticles are important due to their utilization in gas sensors, biosensors, cosmetics, drug-delivery systems, and so forth [6].

Japanese quail, the smallest farmed avian species, is becoming popular in commercial poultry sector for meat and egg production. Distinct include rapid growth, early sexual maturity resulting in short generation interval, high rate of egg laying [7]. Japanese quail have been reported to be more resistant to common poultry diseases [8]. Quail farming may be an alternative to chicken and ducks due to its immense potentiality for meat and egg production, and used as laboratory animals similar to mice and rats [9,10].

Materials and Methods

Animals

The source of quail birds and their breeding method: Fifty quail birds were obtained from the Faculty of Agriculture, Department of Animal Production at the University of Mosul, where the birds were raised in cages suitable for quail birds, and the animals replaced three weeks for adaptation. The birds were divided randomly into five groups distributed into five cages; ten birds were placed in each cage [11].

Experimental design: Oxide zinc nanoparticles, was purchased from (Oma International Trading Authorized Partner of Sigma Germany) at size 5 nm. The birds were treated with two treatments, the acute treatment (20 and 40 ppm) concentrations for three days, while Chronic treatment (5 ppm and 10 ppm) concentrations of zinc oxide nanoparticles for thirty days [12]. In addition to the control group that was dosed daily with distilled water and the groups were divided as follows:

The first and second group is considered the acute treatment group, which treated with the concentration of 20 and 40 ppm at the dose respectively, by oral administration dosed for three days.

The third and fourth group is considered as chronic treatment group, with the concentration of 5 and 10 ppm was orally dosed for a period of thirty days.

The fifth group considered as the control group, oral treated with distilled water for thirty days.

The laboratory animals were dosed orally with 0.5 ml daily in the morning, and the water was raised at night. The animals were sacrificed after three days of dosing and thirty days after dosing. The birds were dissected, the kidney organ was taken with caution, and the organ was fixed with neutralized buffer formalin 10%. The histological sections were made, and by using routine method for preparing the microscopic slides, and examined by light microscope [13].

Histopathological Results

The control group showed the normal tissue of kidney which contains the glomeruli and renal tubules lined by the simple cuboidal epithelial tissue (Figure 1a). The vast majority of epithelial cells lining the renal tubules had significant degeneration and swelling which lead to stenosis lumen (Figure 1b). As for The histological lesions in renal glomeruli characterized by expansion of the Bowman's space which appear as a result of shrinking of mesangial cells of the glomerulus (Figure 1c), these histological changes also showed a difference in size of glomeruli (Figures 1d and

*Corresponding Author: Hanan R. AbdAlaziz, Department of Biology, University of Mosul, Mosul, Iraq; Email: hanan.gp55@student.uomosul.edu.iq

Copyright: © 2021 AbdAlaziz HR, et al. This is an open-access article distributed under the terms of the Creative Commons Attribution License, which permits unrestricted use, distribution, and reproduction in any medium, provided the original author and source are credited.

Received date: 12 June, 2021; **Accepted date:** 26 June, 2021; **Published date:** 03 July, 2021

1e). Hemorrhage was observed. The histopathological examinations clarify differences pathological changes between acute and chronic treatment, which characterized by vascular changes include blood vessels congestion, sever interstitial hemorrhage, reduced renal damage revealed by less degenerative and necrotic lesion in tubular epithelium compared with control group (Figures 2a and 2b). While the 40 ppm showed more severe

pathological effects, like necrosis with pyknosis nuclei of renal epithelial cells, narrowing of Bowman's space was noticed (Figure 2c), and increased hemorrhage and stealth of red blood cell between the urinary tubules and glomerulus and the basement membrane is damage. While the chronic treatment the emergence of slight infiltration of inflammatory cells between the renal tubule (Figures 2d and 2e).

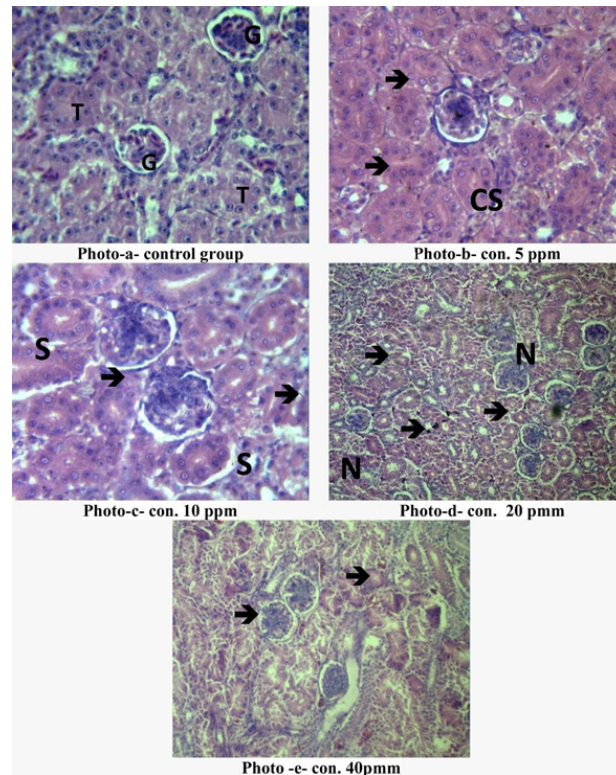


Figure 1. Photomicrograph (1): After three days, showing histological structures through kidney of *Coturnix Coturnix* to different concentrations of zinc oxide nanoparticles (a) showed control group, Glomerula (G) and renal Tubules (T); (b) showing Cloudy Swelling (CS) hemorrhage (→); (c) Sloughing of epithelial cells (S) (40x); (d) and (e) hematoxylin and eosin stain (10x).

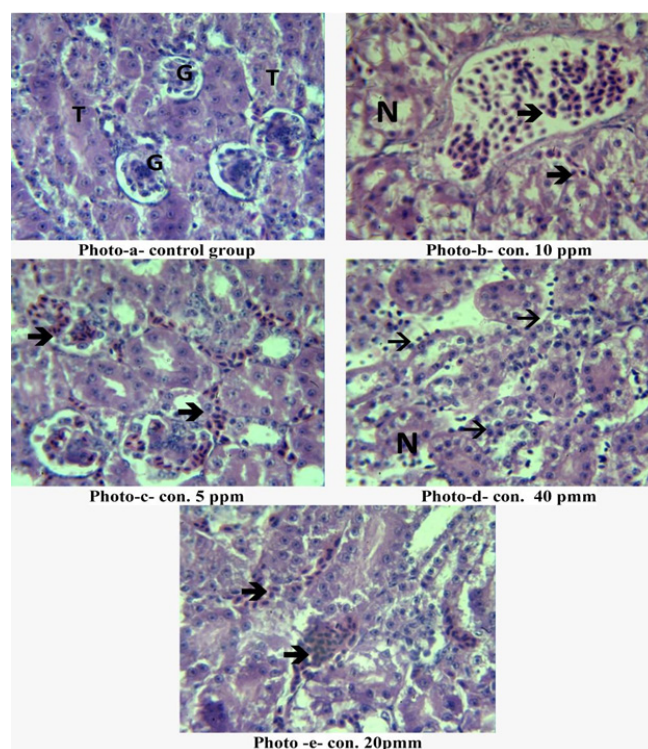


Figure 2. Photomicrograph (2) after 30 days, showing histological structures through kidney of *Coturnix Coturnix* to different concentrations of zinc oxide nanoparticles (a) showed control group, Glomerula (G) and renal Tubules(T); (b) showing hemorrhage (→); (c) and (d) infiltration (→); (e) hematoxylin and eosin stain (40x).

Discussion

The researchers have devoted their efforts to research studies in recent times, the effect of nanomaterials and their effectiveness in different organisms and studies has shown the effect of different nanomaterials to determine the negative and positive effects and develop their horizons. The current results showed the histopathology changes of zinc oxide NPs on the kidneys of birds that dosed for three days at 20 and 40 ppm, and the emergence of severity of damage and hemorrhage between renal tubules, while the cells lining urinary tubules swelling and necrosis when treated with 5 ppm and 10 ppm during the month. This may result from cell damage to increased oxygen stress which shares their strong ability to stimulate increased production of Reactive Oxygen Species (ROS), and the release of Zinc ions, inducing apoptosis [14]. As a study showed that treatment with ZnNP at 20, 40 and 60 mg/Kg showed damage but without toxicity of feeding nanoparticles in laying hens during 55-67 weeks of age [15]. So the nanomaterial was possible application of animal nutrition, the addition of nanoparticles to animal diets has been associated by pathological changes in animal organs. Nanoparticles have also been found to cause inflammatory excitation, and cell death at the cellular level. The growing understanding of nanoparticles potential toxicity to animal organ and necessitates more precise research in the field [5]. Zinc Oxide NP among other metallic nanoparticles, are extremely valuable due to their applications in variety fields [6]. Dietary supplements containing nano composites have been associated with pathological changes in animal tissues. At the cellular level, nanoparticles have been found that induce toxicity, inflammatory excitation, and cell death that correspond with results finding [5]. Nanomaterials show interaction at the molecular level with living cells and tissues, the intake of nutritional supplements containing zinc oxide nanoparticles in quail birds has a harmful effect on the reproduction of male Japanese quail and reduces hatchability [16]. Pinho mentioned that zinc oxide nanoparticles have the ability to induce the production of active oxygen species in addition to that ZnO NPs harm DNA and programmed cell death [17], as ZnONPs are characterized by excitation of toxicity with ease of entry and accumulation in the organism. Zinc oxide nanoparticles have raised toxicity with their ease of entry and accumulation in the organism some concerns and toxicity depends on the concentration and time of exposure, but the effects of any NP also depend on the physical and chemical properties [18]. When that nanomaterials accumulate easily, and their rate of accumulation varies according to tissue type, and that the liver, kidneys, lung, brain, and spleen are the organs that have high levels of ZnO NPs [19]. Siddiqi that zinc oxide nanoparticles disintegrate in the cell membrane and build up in the cytoplasm where they interact with biomolecules, causing apoptosis, leading to cell death. And through the results of the researcher [16]. On the effect of nanoparticle oxide on quail birds. Its toxicity was evaluated in offspring of Japanese quail, fed by breeders with ZnONs. Zinc Nanoparticles for month days cause blood vessels congestion in most kidney tissues, especially in the blood vessels between the renal tubules, the accumulation of inflammatory cells between the renal corpuscles and the tubules, the necrosis of the epithelial cells lining the tubules, the complete loss of some renal glomeruli, the separation of the epithelial cells from the basement membrane and the expansion loosening of Bowman's capsule and enlargement of the nuclei of some epithelial cells lining the renal tubules. The current results are in agreement with the [20]. Al-Zerjawi injected 0.1 ml of nanostructured zinc oxide at a concentration of 150 mg/kg into the peritoneal cavity in white mice for the periods of 7 and 14 days [21]. The researcher stated nanoparticles under acute or chronic exposure can transfer and accumulate in different organs and tissues, leading to adverse effects or systemic toxicity, the kidneys are one of the main organs that are exposed they will be targeted by refractory nanomaterials through various methods. During exposure to engineered nanomaterials, the kidney may become impaired for toxicity. Studies have indicated that exposure of nanoparticles to the kidneys can cause glomerular swelling. Membrane thickening, renal tubular cell degeneration and necrosis. These harmful effects of nanoparticles on the kidneys may be related to oxidative stress, inflammation, autophagy and DNA damage.

According to what emerged from the results, the concentration and the duration of exposure have a different effect on laboratory animal, and this is what the results agree that Zinc is an important component of the overall performance of the animal's body as a significant improvement in the growth performance of birds fed with zinc oxide-rich forage nanoparticles was observed from the diet [22,23]. Where 200 one-week-old Japanese quail was taken and distributed randomly into five treatment groups, and the groups were fed nano-zinc oxide at doses of 0.1, 0.2, 0.3 and 0.4 g/kg of diet respectively [24].

Conclusion

The kidneys are one of the main organs in the body of living things, and one of the most important functions of the kidneys is to drain metabolic wastes and external materials from the blood circulation of the whole body. One of the most important applications of nanomaterial in medicine is the delivery of drugs, and many studies are conducted on these applications, where the nanoparticles work to deliver the drugs that they carry to the diseases. Supplementation of diets with nanoparticles has been accompanied by pathological changes in animal tissues, primarily in the organs.

In this study, quail birds were dosed with zinc oxide nanoparticles orally to assess its potential pathological effect on birds, and based on the results of tissue changes it was concluded that zinc oxide nanoparticles are pathological chemical at determined concentration if exposed to a high concentration in a short period of time or at low concentrations for a period. This poses a danger to living organisms, therefore it is recommended to be careful of nanomaterials in general and zinc oxide nanoparticles in particular and not to be exposed to them for long periods.

Acknowledgments

We would like to thank the University of Mosul, College of Education for Girls, Department of Life Sciences, for giving us this opportunity and Let us express our knowledge.

Conflict of Interest

The current study is part of the master's study and is one of requirements for obtaining master's degree. Included teamwork by researchers, as the work was done with the participation of all researchers to complete the results of the research and write it.

References

1. Khan, Ibrahim, Khalid Saeed, and Idrees Khan. "Nanoparticles: Properties, Applications and Toxicities." *Arab J Chem* 12 (2019): 908-931.
2. Ersöz, Mustafa, Arzum Işıtan, and Meltem Balaban. *Nanotechnology 1: Fundamentals of Nanotechnology*. 10 (2018):251-253.
3. Nikalje, AP. "Nanotechnology and its Applications in Medicine." *Med Chem* 5 (2015): 81-89.
4. Al-obiedy, Amer. "Nanobiotechnology and Advance Application in Medicine and Genetic Engineering and Molecular Biology." 5 (2015): 2285.
5. Bałowski, Maciej, Bożena Kiczorowska, Wioletta Samolińska, and Renata Klebaniuk, et al. "Silver and Zinc Nanoparticles in Animal Nutrition: A Review." *Ann Ani Sci* 18 (2018): 879-898.
6. Sabir, Sidra, Muhammad Arshad, and Sunbal Khalil Chaudhari. "Zinc Oxide Nanoparticles for Revolutionizing Agriculture: Synthesis and Applications." *Sci World J* 9 (2014): 1-7.
7. Hossain, Muhammad Belal, Provas Chandra Sen, Md Abdullah al Noman, and Ariful Islam, et al. "Production Performances of Japanese Quail Parent Stock Under Open Housing System." *J Embry Transfer* 30 (2015): 115-119.

8. Edwin, SC. "Commercial Japanese Quail Production and Disease Management." *Int J Sci Enviro Techno* 9 (2020): 416–422.
9. Berto, Bruno P, Helcio R. Borba, Viviane M Lima, and Walter Flausino, et al. "Eimeria Spp. From Japanese Quails (*Coturnix Japonica*): New Characteristic Features and Diagnostic Tools." *Pes Veteri Brasil* 33 (2013): 1441-1447.
10. Matty, Hiyam N, and Ashwaq A Hassan. "Effect of Supplementation of Encapsulated Organic Acid and Essential Oil Gallant on Some Physiological Parameters of Japanese Quails." *Iraq J Veter Sci* 34 (2020): 181-188.
11. Glatz, P. and Pym, R. "Poultry Housing and Management in Developing Countries." *Food and Agri Organ United Nation Poultry Develop Review* 9 (2013): 24-26.
12. Farzinpour, Amjad, and Naser Karashi. "The Effects of Nano-Silver on Egg Quality Traits in Laying Japanese Quail." *Spring Berlin Heidelberg* 3 (2013): 311-319.
13. Alhaj, A Hamid. *Optical Laboratory Preparation*. Amman: Dar Almasira for Publishing and distribution, Jordan, (2015).
14. Jiang, Jinhuan, Jiang Pi, and Jiye Cai. "The Advancing of Zinc Oxide Nanoparticles for Biomedical Applications." *Bio Chem Appli* 5 (2018): 1-7.
15. Fawaz, Mohamed, Ahmed A Abdel-Wareth, Hamdy Ahmed Hassan, and Karel-Heinz Südekum. "Applications of Nanoparticles of Zinc Oxide on Productive Performance of Laying Hens." *SVU-Int J Agri Sci* 1 (2019): 34-45.
16. Khoobbakht, Zeinab, Roostaei-Ali Mehr, Mehrdad Mohammadi, and Mohammad Mehdi Sohani, et al. "Abnormalities in Unhatched Chicks of Japanese Quails Fed with Zinc Oxide Nanoparticles." *J Dairy Veter Sci* 5 (2018): 1-3.
17. Pinho, Ana Rita, Rebelo Sandra and Pereira, Maria Lourdes. "The Impact of Zinc Oxide Nanoparticles on Male (In) Fertility." *Material* 13 (2015): 849.
18. Chen, Aijie, Xiaoli Feng, Ting Sun, and Yanli Zhang, et al. "Evaluation of the Effect of Time on the Distribution of Zinc Oxide Nanoparticles in Tissues of Rats and Mice: A Systematic Review." *IET Nanobiotechnol* 10 (2016): 97-106.
19. Siddiqi, Khwaja Salahuddin, Aziz ur Rahman, and Azamal Husen. "Properties of Zinc Oxide Nanoparticles and their Activity Against Microbes." *Nanoscale Res Letter* 13 (2018): 1-13.
20. Al-Zerjawe, "Study of the histological and functional changes of particle effect Zinc oxide nanoscale in white male rat quantities." *M Sc. Thesis, University of Baghdad*, (2019): 119.
21. Zhao, Haiyang, Luxin Li, Huilu Zhan, and Yanhui Chu, et al. "Mechanistic Understanding of the Engineered Nanomaterial-Induced Toxicity on Kidney." *J Nano* 9 (2019): 1-12.
22. Reda, FM. El-Saadony, MT El-Rayes, and TK Attia, et al. Use of Biological Nano Zinc as a Feed Additive in Quail Nutrition: Biosynthesis, Antimicrobial Activity and its Effect on Growth, Feed Utilisation, Blood Metabolites and Intestinal Microbiota. *Ital J Ani Sci* 20 (2021):324–335.
23. AL-Nakeeb, Gazwa D, and Abeer S Abd Ali. "Effect of Silver Nanoparticles in the Liver of Female Quail (*Coturnix Coturnix*)." *Bagh Sci J* 12 (2015): 645-656.
24. Rajak. "Nanotechnology and Its Application, Journal of Nanomedicine & Nanotechnology." *Visva-Bharati University* 9 (2018):591-605.

How to cite this article: AbdAlaziz, Hanan R and Azhar A Albaker. "Histological Effect of Zinc Oxide Nanoparticles on Kidney of Japanese Quail *Coturnix coturnix*." *Clin Schizophr Relat Psychoses* 15: S4(2021). Doi: 10.3371/CSRP. AAAH.072821.