

Prolonged Catatonic Stupor Successfully Treated with Aripiprazole in an Adolescent Male with Schizophrenia: A Case Report

Eiji Kirino^{1,2}

Abstract

We present the case of a fifteen-year-old adolescent male with schizophrenia who had long-term catatonic stupor and was successfully treated with aripiprazole. The onset of his stupor manifested rapidly after experiencing prodromal symptoms for two months. He was left untreated without adequate food ingestion for three weeks because of his parents' religious faith, and was severely dehydrated and malnourished upon admission to our hospital. After his physical recovery, treatment with risperidone (0.5–2.0 mg, 5 weeks) was started. However, hypersedation occurred, and the risperidone was switched to aripiprazole, with dose increases up to 18 mg/day (5 months). As a result, he recovered from his totally noncommunicative state. Aripiprazole, which has a unique pharmacological mechanism of action distinct from other atypical antipsychotics and an excellent safety profile, may be effective in the treatment of some schizophrenic patients with stupor, which sometimes carries a risk of physical debilitation and requires special attention due to the risk of adverse drug reactions.

Key Words: Aripiprazole, Schizophrenia, Catatonic Stupor, Adolescence

Case Report

The patient was a fifteen-year-old Japanese male who attended a junior high school. He was the second of three children, born in Prefecture A in Japan. The patient had no previous personal or family history of schizophrenia or any other psychiatric disorder. His birth was normal. His language development was slightly delayed, but he had no motor development problems. He graduated from a local elementary school then entered a local junior high school.

The boy was introverted and unsociable. He was the victim of bullying during his junior high school years, and gradually stopped going to school. His parents belonged to a new religious organization, and his father worked at an affili-

ated medical site of the same organization. His mother used to work as a nurse at this site. The bullying had escalated since October of year X (when the patient was fifteen-years old). He was beaten by his classmates and forced to go on errands for them. A marked truancy history was observed afterward, and he stopped going to school completely in mid-November of the same year. He talked less and less after these events. In December, his appetite gradually decreased, and he withdrew to his room. He expressed unreasonable hostility toward his parents.

On the night of January 2 of year X+1, he suddenly made grimaces and shouted excitedly, "I have taken over this lad's body." "I've lost my face." "Someone's chasing me." "I've just come back from the war," and "I am the man who died thirty years ago," etc. He tried to rush out of his home, but his parents stopped him. After these episodes were repeated for a few days, verbal communication was no longer possible. The boy stayed in bed all day with his eyes open, but did not speak. It was difficult for him to take foods orally. His parents stuck to their faith that natural healing would cure the disease, and did not bring their son to a hospital. No

¹Department of Psychiatry, Juntendo University School of Medicine

²Department of Psychiatry, Juntendo University Shizuoka Hospital

Address for correspondence: Eiji Kirino, Juntendo University Shizuoka Hospital, 1129 Nagaoka Izunokunishi, Shizuoka 4102211, Japan
Phone: +81 (55) 948-3111; Fax: +81 (55) 948-5088;
E-mail: ekirino@juntendo.ac.jp

Submitted: May 8, 2009; Revised: October 5, 2009;

Accepted: November 19, 2009

improvement was seen and his emaciation became marked, until finally on 23 January of year X+1 he was brought to Clinic B, an affiliated site of the religious organization to which his parents belonged.

Afterward, he was transferred by ambulance and admitted to the department of internal medicine of our hospital, General Hospital C, due to severe dehydration and malnutrition. He was in a stupor where he spontaneously opened his eyes, but he remained unexpressive and did not respond when we spoke to him. He also had systemic stiffness, as well as contracture of the joints in both his upper and lower extremities. His posture was catalepsy-like because he maintained an unusual posture accompanied by external manipulations of the limbs (rather than due to contracture of the joints). Although his eyes moved slightly in response to our voices, he had difficulty communicating with others. To exclude the possibility of organic brain diseases, a physical examination was ordered upon admission, and included a brain computed tomography (CT) scan, magnetic resonance imaging (MRI), encephalogram (EEG), and blood examinations. These tests were conducted, but there were no remarkable findings, except for the patient's creatinine phosphokinase (CPK) levels. Although the patient's CPK levels were increased (42,500 IU/l), clinical symptoms and other blood chemistry tests were not consistent with the diagnosis of rhabdomyolysis; glutamic oxaloacetic transaminase (GOT) 470 IU/l; glutamic pyruvic transaminase (GPT) 98 IU/l; lactate dehydrogenase (LDH) 1,610 IU/l; blood urea nitrogen (BUN) 77.1 mg/dl; and, creatinine 0.8 mg/dl. Intravenous hyperalimentation immediately improved the boy's dehydration. Spinal puncture and single photon emission computed tomography (SPECT) was not conducted because the parents' consent was not obtained.

A diagnosis of schizophrenia was made because the boy had psychomotor excitability, hallucinations and delusions before he experienced stupor, and there were insufficient findings to suggest organic cerebral disease. Major depressive disorder with psychosis or schizoaffective disorder was considered in the differential diagnosis. Major depressive disorder was ruled out because his delusion was neither empathically comprehensive nor a psychopathological manifestation of an affective disorder. Schizoaffective disorder was ruled out as well because definitive depressive symptoms were not recognized, although the boy was withdrawn from his family and school. Nasogastric administration of risperidone oral solution 0.5 mg/day, which was chosen because of its convenience of administration, was commenced on February 5 after the levels of CPK returned to a normal level (43 IU/l). When the dose was increased to 2 mg/day, the patient began to look drowsy, even during the daytime, which appeared to be due to hypersedation by risperidone. Therefore, his antipsychotic medication was switched from

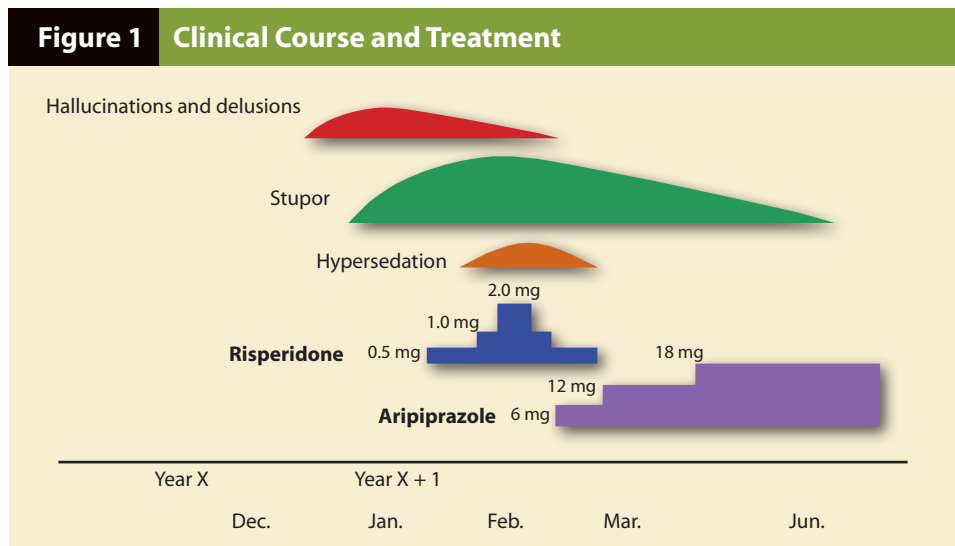
risperidone to aripiprazole, at a starting dose of 6 mg/day, on March 9. Aripiprazole was administered in powder form because an oral solution was not available in Japan at that time. Aripiprazole was gradually increased while the risperidone dose was tapered off. After aripiprazole was increased to 12 mg/day on March 13, the boy began to speak in two- or three-word phrases and visually track objects and people. Aripiprazole was increased to a dose of 18 mg/day on March 20 to confirm safety and to improve efficacy, after which his communication ability improved further. He began expressing his will to talk to his mother or to go home. His systemic stiffness and joint contracture were also improved. In early April, he had recovered enough to play *Shiritori*, a Japanese word game, with the nurses. He was able to show emotions such as feeling sullen or joyful through facial expressions. Rehabilitation also helped him to become able to feed himself. He was then transferred to the psychiatric department of Hospital D. He remained on aripiprazole at the same dose after his transfer. Two months later, he had recovered to almost the same state as before the stupor event occurred, and was discharged from the hospital (see Figure 1). At that time, he expressed his emotions naturally and his quality of life (QOL) was improved after discharge such that he could go back to school and enjoy basketball.

Discussion

Catatonia is an infrequent but severe condition in children and adolescents, and is usually associated with schizophrenia, affective disorders or other psychotic illnesses (1-3). Studies in adult patients with major psychiatric disorders (schizophrenia, affective disorders, and other psychotic illnesses) have been reported at an incidence rate of 10 to 37.7% (4-7). Catatonia in young people has been understudied. The incidence (0.6-5.5) and the most frequent diagnosis (schizophrenia or major depression) in young people varies in the literature (1-3). The symptoms are characterized by the coexistence of psychic and motor symptoms such as stupor/immobility, posturing/catalepsy, psychomotor automatism, rigidity and negativism (1, 2).

Ethnic and cultural factors might be associated with the clinical manifestations of catatonia in adolescents (2, 3), as well as in adults. In Cohen's reports (1), automatic compulsive movements and stereotypies were highly suggestive of schizophrenia, but stupor cannot be regarded as specific for a diagnostic class.

Our patient was characterized by a prolonged stupor due to both acute psychotic symptoms and physical debilitation resulting from dehydration and malnutrition. His parents' religious faith was a factor in delaying medical intervention. At first, the patient's consciousness was not sufficiently recovered and risperidone oral solution was chosen because of its convenience for nasogastric administration.

Figure 1 Clinical Course and Treatment

Hypersedation followed the risperidone treatment, which made it difficult to evaluate the effects of the antipsychotic medication. Therefore, the risperidone was switched to aripiprazole, which has little sedative effect compared with other atypical antipsychotics, an excellent safety profile, and pharmacological actions that are distinct from other drugs.

Aripiprazole, the world's first dopamine system stabilizer (DSS), is also called a partial dopamine D2 receptor agonist (8, 9). Aripiprazole has a higher affinity for dopamine D2 receptors than dopamine, a full agonist, in the brain (8). This pharmacological action was demonstrated as having efficacy over hallucinations and delusions in short-term (10, 11) and long-term clinical trials in patients with acute relapse of schizophrenia (12, 13). Aripiprazole also has high affinity for serotonin 5-HT1A receptors and 5-HT2A receptors. It acts as a partial agonist on 5-HT1A receptors (14), and as an antagonist on 5-HT2A receptors (15). Its partial agonism at the 5-HT1A receptor plays a significant role in its antianxiety effect and low incidence of extrapyramidal symptoms (EPS), and its antagonism at the 5-HT2A receptor also decreases EPS. Given this profile, aripiprazole is expected to cause few EPS (16). In addition, aripiprazole has low or almost no affinity for adrenalin (α -1) receptors, histamine (H1) receptors, and muscarinic (M1) receptors which are associated with adverse effects like cardiovascular abnormalities, weight gain and hypersedation, suggesting a better safety profile for aripiprazole (17).

In the case of catatonic schizophrenia, antipsychotic drugs have been recommended (18), but lack of efficacy or worsening of catatonic symptoms frequently occurs. Neuroleptics (especially first-generation antipsychotics) have been associated with a risk of adverse effects such as EPS or malignant catatonia (i.e., neuroleptic malignant syndrome) (3, 19, 20). Previous reports suggested that atypical antipsychotics are effective in treating catatonic stupor in schizo-

phrenic patients (21, 22), but the evidence is limited to case reports and retrospective studies (23), making it necessary to prescribe them carefully. Catatonic stupor is thought to result from blockage of D2 receptors in the striata or a regulation disorder in the motor cortex, although the mechanism remains to be elucidated (24). Some patients with first-episode schizophrenia often exhibit the catatonic type or the disorganized type, and atypical antipsychotics with few EPS may be effective in catatonic-type schizophrenia (25). The use of electroconvulsive therapy may be indicated in cases of malignant subtype or refractoriness to pharmacotherapy, or life-threatening conditions (3, 26-28).

Regarding the use of aripiprazole for children and adolescents, a multi-center, randomized, double-blind, placebo-controlled study found that aripiprazole was generally well tolerated, with a low rate of discontinuations due to adverse events and a high completion rate in adolescents with schizophrenia. These results provide support for aripiprazole use in adolescents with schizophrenia at a starting dose of 2 mg/day, and provide evidence of efficacy and tolerability at the recommended adult doses, ranging from 10 to 30 mg/day (29). Given the safety profile and efficacy, a case report (20) also suggests that aripiprazole may be considered early in the treatment of children or adolescents with psychosis accompanied by catatonia, particularly those who have had suboptimal response to benzodiazepines.

Our patient was a case of first-episode schizophrenia, which requires special attention due to the adverse reactions to drugs. If the dose of antipsychotics is increased in order to control delusions and hallucinations in young patients, EPS or hypersedation often occurs, making it difficult to increase the dose. A key to a successful outcome is to choose an appropriate drug given the pharmacological attributes. Catatonia may be particularly critical, and prolonged catatonia can lead to complications such as pulmonary embolism and

bladder infection (2, 30, 31). Aripiprazole's partial agonism of the D2 receptor, rather than completely blocking dopaminergic activity (32), might lead to less risk of hypersedation and improve communication ability and QOL as observed in the present case, although QOL was only assessed by observation and not measured on any scale. Furthermore, its partial agonism of the 5-HT_{1A} receptor might have had a significant antianxiety effect in his catatonic state. Hence, aripiprazole may be beneficial for patients with catatonia.

A specific background of the present case is that the parents' negativism against the medical care due to their religious faith delayed their first consultation with the hospital for more than a month. Even after admission, they were not provided enough understanding of the necessity for appropriate examination and treatment, including pharmacological therapy. That is another reason we paid special attention to the adverse reactions to drugs. Our choice of antipsychotics resulted in aripiprazole being selected, and it eventually turned out to be therapeutically relevant. In our experience and in the literature (3), managing the family's reactions and fears is essential to avoid noncooperation. In this case, if the family negativism had been greater and the family uncooperative, we would have had to consider this case as religion-motivated medical neglect.

Like the five months in the present case, hospitalization time in Japan is generally longer than in western countries. This is the case with the general hospital, the psychiatric hospital, or the rehabilitation hospital in Japan. That may be due to the difference in medical service systems and insurance, or to cultural differences between countries. In our case, it took a long time for the patient and his family to understand the necessity of appropriate treatment. A longer hospitalization time was beneficial in this case to establish a relationship of mutual trust between the patient, the family and the psychiatrists.

References

1. Cohen D, Nicolas JD, Flament MF, Perisse D, Dubos PF, Bonnot O, et al. Clinical relevance of chronic catatonic schizophrenia in children and adolescents: evidence from a prospective naturalistic study. *Schizophr Res* 2005;76(2-3):301-308.
2. Thakur A, Jagadheesan K, Dutta S, Sinha VK. Incidence of catatonia in children and adolescents in a paediatric psychiatric clinic. *Aust N Z J Psychiatry* 2003;37(2):200-203.
3. Cohen D, Flament M, Dubos PF, Basquin M. Case series: catatonic syndrome in young people. *J Am Acad Child Adolesc Psychiatry* 1999;38(8):1040-1046.
4. Taylor MA, Abrams R. Catatonia. Prevalence and importance in the manic phase of manic-depressive illness. *Arch Gen Psychiatry* 1977;34(10):1223-1225.
5. Rosebush PI, Hildebrand AM, Furlong BG, Mazurek MF. Catatonic syndrome in a general psychiatric inpatient population: frequency, clinical presentation, and response to lorazepam. *J Clin Psychiatry* 1990;51(9):357-362.
6. Braunig P, Kruger S, Shugar G. Prevalence and clinical significance of catatonic symptoms in mania. *Compr Psychiatry* 1998;39(1):35-46.
7. Banerjee A, Sharma LN. Catatonia incidence in acute psychiatric admissions. *Indian Journal of Psychiatry* 1995;37(1):35-40.
8. Burris KD, Molski TF, Xu C, Ryan E, Tottori K, Kikuchi T, et al. Aripiprazole, a novel antipsychotic, is a high-affinity partial agonist at human dopamine D2 receptors. *J Pharmacol Exp Ther* 2002;302(1):381-389.
9. Tadori Y, Miwa T, Tottori K, Burris KD, Stark A, Mori T, et al. Aripiprazole's low intrinsic activities at human dopamine D2L and D2S receptors render it a unique antipsychotic. *Eur J Pharmacol* 2005;515(1-3):10-19.
10. Kane JM, Carson WH, Saha AR, McQuade RD, Ingenito GG, Zimbroff DL, et al. Efficacy and safety of aripiprazole and haloperidol versus placebo in patients with schizophrenia and schizoaffective disorder. *J Clin Psychiatry* 2002;63(9):763-771.
11. Potkin SG, Saha AR, Kujawa MJ, Carson WH, Ali M, Stock E, et al. Aripiprazole, an antipsychotic with a novel mechanism of action, and risperidone vs placebo in patients with schizophrenia and schizoaffective disorder. *Arch Gen Psychiatry* 2003;60(7):681-690.
12. Kasper S, Lerman MN, McQuade RD, Saha A, Carson WH, Ali M, et al. Efficacy and safety of aripiprazole vs. haloperidol for long-term maintenance treatment following acute relapse of schizophrenia. *Int J Neuropsychopharmacol* 2003;6(4):325-337.
13. Kern RS, Green MF, Cornblatt BA, Owen JR, McQuade RD, Carson WH, et al. The neurocognitive effects of aripiprazole: an open-label comparison with olanzapine. *Psychopharmacology (Berl)* 2006;187(3):312-320.
14. Jordan S, Koprivica V, Chen R, Tottori K, Kikuchi T, Altar CA. The antipsychotic aripiprazole is a potent, partial agonist at the human 5-HT_{1A} receptor. *Eur J Pharmacol* 2002;441(3):137-140.
15. Hirose T, Uwahodo Y, Yamada S, Miwa T, Kikuchi T, Kitagawa H, et al. Mechanism of action of aripiprazole predicts clinical efficacy and a favourable side-effect profile. *J Psychopharmacol* 2004;18(3):375-383.
16. Marder SR, McQuade RD, Stock E, Kaplita S, Marcus R, Safferman AZ, et al. Aripiprazole in the treatment of schizophrenia: safety and tolerability in short-term, placebo-controlled trials. *Schizophr Res* 2003;61(2-3):123-136.
17. American Psychiatric Association. Practice guideline for the treatment of patients with schizophrenia, second edition. Available from: URL: http://www.psychiatryonline.com/pracGuide/pracGuideTopic_6.aspx.
18. Fink M. Catatonia in DSM-IV. *Biol Psychiatry* 1994;36(7):431-433.
19. Philbrick KL, Rummans TA. Malignant catatonia. *J Neuropsychiatry Clin Neurosci* 1994;6(1):1-13.
20. Strawn JR, Delgado SV. Successful treatment of catatonia with aripiprazole in an adolescent with psychosis. *J Child Adolesc Psychopharmacol* 2007;17(5):733-735.
21. Kopala LC, Caudle C. Acute and longer-term effects of risperidone in a case of first-episode catatonic schizophrenia. *J Psychopharmacol* 1998;12(3):314-317.
22. Tan QR, Wang W, Wang HH, Zhang RG, Guo L, Zhang YH. Treatment of catatonic stupor with combination of modified electroconvulsive treatment and olanzapine: a case report. *Clin Neuropharmacol* 2006;29(3):154-156.
23. Van Den Eede F, Van Hecke J, Van Dalfsen A, Van den Bossche B, Cosyns P, Sabbe BG. The use of atypical antipsychotics in the treatment of catatonia. *Eur Psychiatry* 2005;20(5-6):422-429.
24. Northoff G. Catatonia and neuroleptic malignant syndrome: psychopathology and pathophysiology. *J Neural Transm* 2002;109(12):1453-1467.
25. Carroll BT. Kahlbaum's catatonia revisited. *Psychiatry Clin Neurosci* 2001;55(5):431-436.
26. Chung A, Varghese J. Treatment of catatonia with electroconvulsive therapy in an 11-year-old girl. *Aust N Z J Psychiatry* 2008;42(3):251-253.
27. Esmaili T, Malek A. Electroconvulsive therapy (ECT) in a six-year-old girl suffering from major depressive disorder with catatonic features. *Eur Child Adolesc Psychiatry* 2007;16(1):58-60.
28. Zaw FK. ECT and the youth: catatonia in context. *Int Rev Neurobiol* 2006;72:207-231.
29. Findling RL, Robb A, Nyilas M, Forbes RA, Jin N, Ivanova S, et al. A multiple-center, randomized, double-blind, placebo-controlled study of oral aripiprazole for treatment of adolescents with schizophrenia. *Am J Psychiatry* 2008;165(11):1432-1441.
30. Ainsworth P. A case of 'lethal catatonia' in a 14-year-old girl. *Br J Psychiatry* 1987;150:110-112.
31. Cornic F, Consoli A, Tanguy ML, Bonnot O, Perisse D, Tordjman S, et al. Association of adolescent catatonia with increased mortality and morbidity: evidence from a prospective follow-up study. *Schizophr Res* 2009;113(2-3):233-240.
32. Kurahashi N. Attributes of aripiprazole, a third generation antipsychotic. *BIO-Clinica* 2007;22(8):719-725.